

AUGUST 2010
CASE OF THE MONTH

Interesting Case of Anisocoria

UPDATE


We are happy to announce that both Bush Veterinary Neurology Service and Bush Advanced Veterinary Imaging have expanded our services by opening a second imaging site and neurology practice at Regional Veterinary Referral Center in Springfield, VA. Both services are open Monday-Thursday 8:00 am – 5:00 pm. Imaging is available for in-hospital services as well as direct referral from local hospitals.

LEARN ABOUT VETERINARY MRI

Technology is changing the way we practice medicine but it can be very difficult keeping up with all of the advances. Let us help. We are available to meet with you and your staff to discuss the value of MRI and CT imaging in the practice of veterinary medicine. Call us today to arrange a meeting. We'd be happy to bring in breakfast, lunch, or dinner.

info@bushvetimaging.com
www.bushvetimaging.com

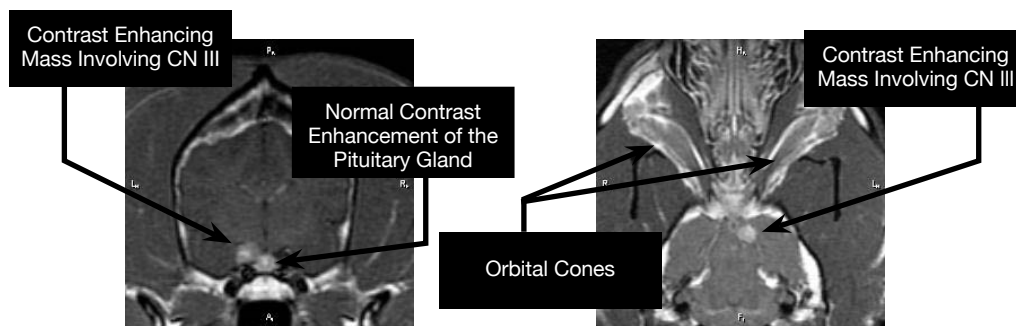
Signalment, History, and Physical Exam Findings



Ziggy is a 9 Year old spayed female German Shepherd mix who presented to Dr. Joli Jarboe of Bush Veterinary Neurology Service for a one month duration of anisocoria with the left pupil dilated greater than the right. Cranial nerve examination revealed the anisocoria to be present in all lighting, both direct and indirect pupillary light reflexes were absent. Menace response remained intact. Mild ptosis and enophthalmos were present OD and on palpebral reflex stimulation there was decreased motion of the upper and lower palpebra.

Lesion Localization and Differential Diagnosis

Ziggy's disease was felt to be caused by plegia of cranial nerve III on the left side of the brain, with subtle evidence of paresis of left cranial nerves IV, VI, and ophthalmic branch of V. These deficits pointed towards a disease process involving the nerves near the orbital fissure, along the floor of the middle cranial fossa, near the cavernous sinus region. Neoplasia, infectious (most commonly protozoal), or immune mediated diseases were considered the most likely differential diagnoses.



T1 Weighted Post Contrast Axial Image

T1 Weighted Post Contrast Coronal Image

MRI Findings

An MRI of the brain was performed. T1 weighted post contrast imaging showed a contrast enhancing mass in the region of the left third cranial nerve. The mass undergoes intense and uniform contrast enhancement. While neuritis is possible, given the history and sharp demarcation of the mass, it is suspected to be a nerve sheath tumor of the third cranial nerve.

Conclusion

Tumors of the third cranial nerve are not common, but following tumors of the fifth cranial nerve, it is one of the more common nerves affected within the canine brain. Stereotactic radiosurgery or rotational single dose radiotherapy is often highly effective in controlling the growth of these tumors. Ziggy recently finished a full course of radiation and on follow up with the owner is doing well at home. We hope to re-image Ziggy in 3 months to see what impact radiation therapy had on this mass.